European-African Hepato-Pancreato-Biliary Association

E-AHPBA

E-AHPBA Webinars

Bile Duct

Wednesday 28th October 2020
1800 BST / 1900 CEST

@eahpba

www.eahpba.org

European-African Hepato-Pancreato-Biliary Association

E-AHPBA

Diagnostic assessment of Biliary strictures

Sean Burmeister

University of Cape Town
Groote Schuur Hospital

Conflict of Interest

I declare I have no conflict of interest

European-African Hepato-Pancreato-Biliary Association

Social Media

You are welcome to share details of this presentation responsibly and with due credit on social media.

Introduction

- Accurate assessment of biliary strictures is essential **to avoid inappropriate interventions** for benign conditions **while not missing malignant disease**
- Multiple modalities exist for evaluating biliary strictures with those chosen dependant on each case's characteristics
- Critical role of multidisciplinary input

Benign	Nepolastic
Previous surgery (cholecystectomy, transplantation)	cholangiocarcinoma
Pancreatitis (acute, chronic, AIP)	Pancreatic carcinoma
PSC	Peri-ampullary carcinoma
Secondary sclerosing cholangitis (IgG4-SC, recurrent pyogenic cholangiopathy, AIDS cholangiopathy, chemotherapy)	Gallbladder carcinoma
Mirrizzi syndrome	Lymphoma
TB	NET
Choledocholithiasis	

Introduction

- Accurate assessment of biliary strictures is essential to avoid inappropriate interventions for benign conditions while not missing malignant disease
- **Multiple modalities** exist for evaluating biliary strictures with those chosen dependant on each case's characteristics
- Critical role of **multidisciplinary** input

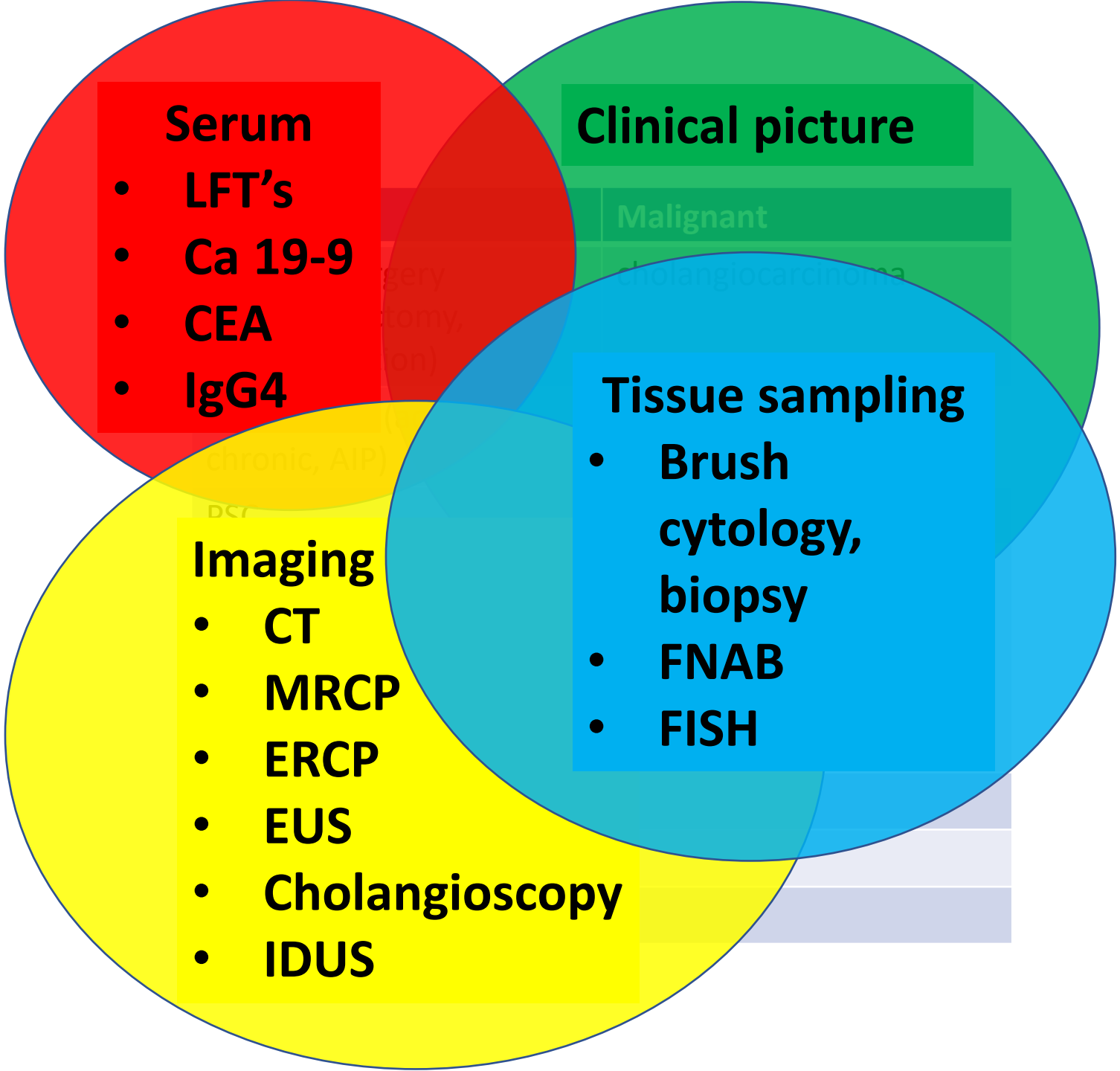

Clinical picture – asymptomatic

Incidentally Identified Common Bile Duct Dilatation

A Systematic Review of Evaluation, Causes, and Outcome

Ioana Smith, MD, Klaus Monkemuller, MD, PhD, and C. Mel Wilcox, MD, MSPH

- Distinction between symptomatic / asymptomatic
- Incidentally discovered Biliary strictures are **most** often **benign** although **malignancy** can be found in **0-15%** (PDAC, cholangiocarcinoma).
- Of incidental cases, a **cause** for biliary dilatation was found in 9-73% of patients, **average 33%.**
- Commonest causes: **CBD stone, chronic pancreatitis, peri-ampullary diverticulum**

Smith J Clin Gastro 2015

Clinical picture – symptomatic

- Symptoms such as **jaundice, pruritus and fatigue non-specific**
- **Pain and fever** suggest bacterial cholangitis
- **Background medical history**

  - Thorough interrogation for **causes of secondary sclerosing cholangitis, features of acute / chronic pancreatitis, previous surgery, malignant risk factors / symptomatology** (PSC, smoking, etoh, longstanding IBD, age, UC with colonic malignancy, CP, DM, exocrine insufficiency, weight loss, BMI, heredity)

  - **Chronic pancreatitis**
    - **Biliary strictures** complicate **3-23%** of patients with 30-50% developing jaundice. Typically occurs in **advanced disease** and is often **transient**. Etoh, smoking, younger age, diffuse pancreatic ductal changes suggest CP

Dumonceau Ther Adv Gastro 2020

Clinical picture – symptomatic

- Background medical history
  - **Inflammatory bowel disease** associated with 60-90% of **PSC**; UC 5x more frequent than Crohn's. PSC patients have an annual incidence of cholangiocarcinoma of 0.5-2% with a lifetime risk of 10-20%.
  - **Post-surgical**: complicated **cholecystectomy, transplantation** - **anastomotic** (6-12% deceased donor, 34% living donor), **non-anastamotic** (>5mm from anastomosis – ischaemic or receiver disease related).
  - Patients with **ischaemic cholangiopathy** may have history of surgery, intra-arterial chemotherapy, portal hypertension, thrombosis inducing drugs
  - **AIDS cholangiopathy**: typically advanced disease with CD4 count <100/mm^3

Dumonceau Ther Adv Gastro 2020

Clinical picture – symptomatic

- Features associated with specific malignancies
  - **Pancreatic Carcinoma**
    - Progressive painless jaundice; weight loss; delayed pain; acute pancreatitis without apparent causative factor; recent onset diabetes; unexplained thrombophlebitis; dilated gallbladder; ascites
  - **Cholangiocarcinoma**
    - Jaundice, discomfort, weight loss potential features. Cholangitis is rare

Dumonceau Ther Adv Gastro 2020

Clinical picture - biochemistry, biomarkers

ORIGINAL ARTICLE

Malignant biliary strictures in patients with a normal bilirubin and/or normal liver enzymes

Sarah C. Thomasset, David Saunders, Adele Holland, Ashley R. Dennison & Giuseppe Garcea

Department of Hepatobiliary and Pancreatic Surgery, University Hospitals of Leicester, Leicester, UK

- 830 patients with biliary strictures evaluated
- **6%** of patients with **primary hepatobiliary cancers** may present with **normal bilirubin, ALP and ALT**
  - In this group, hypoalbuminaemia and intra-hepatic duct dilatation were associated with malignancy
- % of malignant diagnoses with biliary strictures and normal bilirubin levels: 21% of pancreatic cancer patients; 13% of ampullary cancers; 7% of distal cholangiocarcinomas; 9% of hilar cholangiocarcinomas.

Thomasset HPB 2015

Clinical picture - biochemistry, biomarkers

- **Ca 19-9 / CEA**
  - **Ca 19-9 current gold standard** tumour marker – only one approved by FDA
    - Sensitivity / specificity 75%/ 75-84% for PDAC & cholangioCa
  - Superior to CEA for PDAC with similar specificity; combination increases sensitivity
  - **Limitations** in terms of sensitivity (**80-90%% penetrance** of required enzyme) and specificity (false elevation in **biliary obstruction**, **other tumours**); can be improved by excluding patients with low biosynthesis
- IgG4
  - IgG4 >130-140mg/dl has sensitivity / specificity of 72% & 93% for distinguishing AIP from pancreatic cancer
  - **Elevated in 10% of PSC** patients
- PSC:
  - At diagnosis **aminotransferases are typically <300IU/L with normal bilirubin** levels.

Dumonceau Ther Adv Gastro 2020
Liang Med Sci Monitor 2015
Zhang Int J Clin Exp Med 2015

Imaging – Cholangiography

- **MRCP** represents the standard in terms of **non-invasive characterisation** of biliary strictures
  - **Diffusion weighted imaging** can aid diagnosis of malignant disease

- **Appearance** of the stricture and associated features are important clues to aetiology
  - **Chronic pancreatitis:** smooth, tapered stricture; associated features on cross-sectional imaging (parenchymal atrophy, calcifications, dilated pancreatic duct, features of AIP)
  - **Ischaemic cholangiopathy:** Multiple, smooth intra- and extra-hepatic ductal strictures with diffuse irregularity
  - **Post-transplantation:** non-anastomotic strictures multiple, longer than anastomotic strictures, may be intra-hepatic

Dumonceau Ther Adv Gastro 2020

Imaging – Malignant disease

- **Features** suggestive of malignant disease
  - **Duct hyper-enhancement / thickness; longer, irregular, asymmetric strictures; regional node enlargement >1cm; abrupt cut-off**

  - **Pancreatic cancer:**
    - **CT** generally recommended for diagnosis, staging and assessment of resectability. Presence of a **mass** lesion is highly suggestive while combined biliary / pancreatic ductal dilatation and parenchymal atrophy also raise suspicion.
    - Transabdominal US, MRI, EUS have similarly high accuracy in detection

  - **Cholangiocarcinoma:**
    - **CT/MRI**: typically demonstrate a dilated proximal biliary system; **mass lesion may not be evident. MRI/MRCP** is accurate for identifying strictures **but less good for differentiating benign from malignant** lesions. Interpretation aided by T1/T2/Diffusion weighted imaging.
    - Evaluation of longitudinal extent remains challenging

Imaging – Cholangiography

- **Invasive procedures** reserved for where **decompression** is mandated or a **tissue diagnosis** is required (ERCP, cholangioscopy, EUS)
  - Risk of sepsis in potentially static system
- **Site** of the stricture helps guide **subsequent** more invasive **investigation**
  - **Hilar strictures** are more suited to **ERCP, cholangioscopy** – avoid EUS FNA
  - **Extra-hepatic** lesions are usually well seen on **EUS**
- **Multi-focality** is more in keeping with benign / inflammatory causes
  - **PSC:** Intra- & extra-hepatic disease (70%); Intra-hepatic alone (25%); extra-hepatic alone (5%).

Dumonceau Ther Adv Gastro 2020
Bjornsson Am J Gastro 2004
Chapman Eur J Gastroenterol Hep 2012
Chapman Gut 2019

Imaging – Cholangiography

- Inflammatory diseases
  - PSC vs IgG4

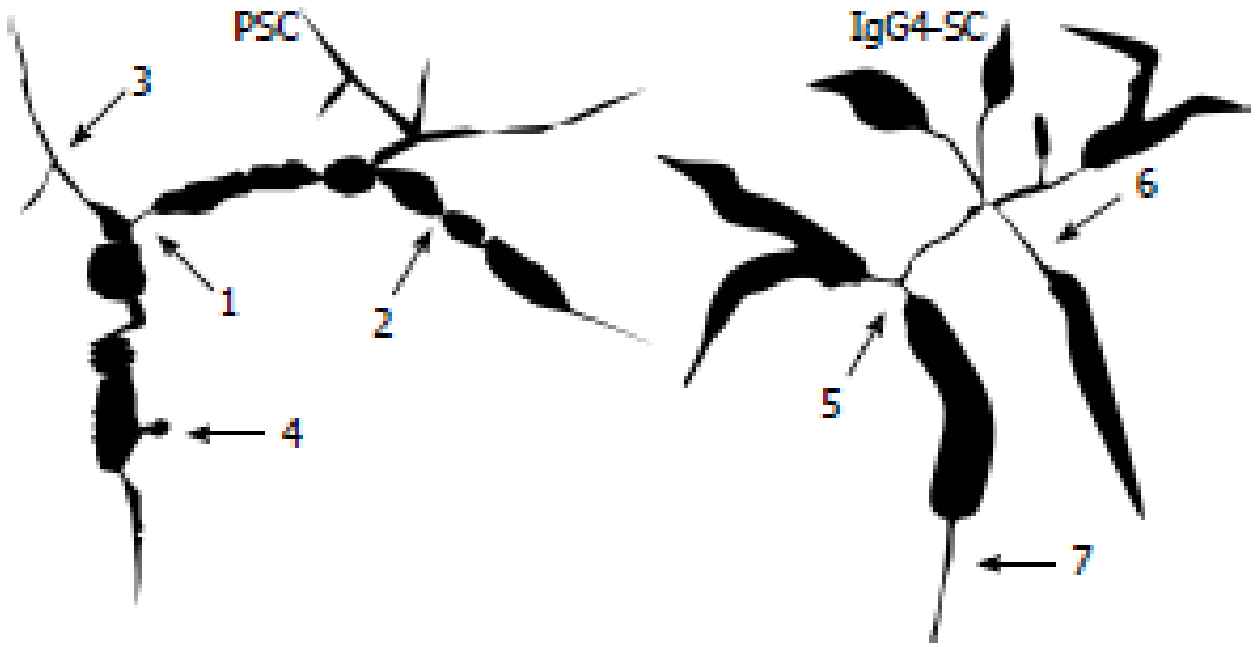

IgG4 also

- IgG4 more frequently **painless** jaundice (75% vs 5-30%), **older** pt's (62 vs 40yrs)
- **Cholestasis, ↑IgG4** hallmarks
- **Ca 19-9** may be elevated
- **Steroid responsive**
- **No IBD**
- Not pre-malignnat

Kamisawa J Hepatobil Panc Sci 2019

Imaging – Cholangiography

- IgG4 cholangiopathy
  - Varied **appearances determine differential** diagnosis and **investigative approach**
  - Association with auto-immune pancreatitis **AIP – HISORt** criteria diagnostic

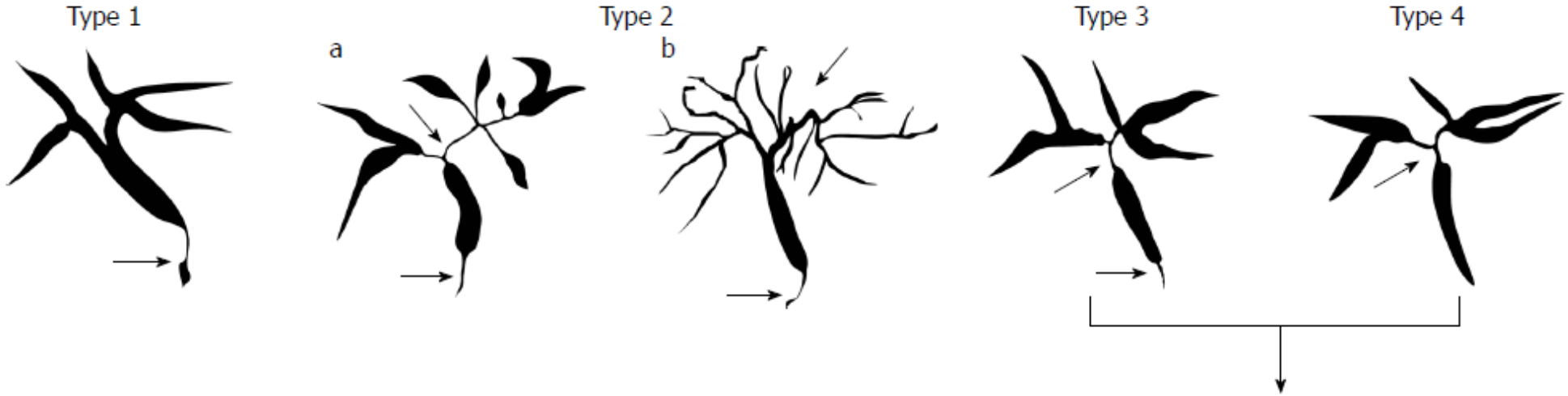

	Type 1	Type 2	Type 3 / Type 4
Differential diagnosis	Pancreatic cancer Bile duct cancer Chronic pancreatitis	Primary sclerosing cholangitis	Bile duct cancer Gallbladder cancer
Useful modalities	IDUS (bile duct) EUS-FNA (pancreas) Biopsy (bile duct)	Liver biopsy Colonoscopy (R/O coexistence of IBD)	EUS (bile duct, pancreas) IDUS (bile duct) Biopsy (bile duct)

Kamisawa J Hepatobil Panc Sci 2019

Imaging – Cholangiography

- PSC
  - **Dominant strictures** in PSC develop in up to 50% of patients and represent a particular challenge requiring careful evaluation.
  - 50% of CCA's diagnosed within 1 year of PSC diagnosis
  - Concern if clinical deterioration, progressive dilatation

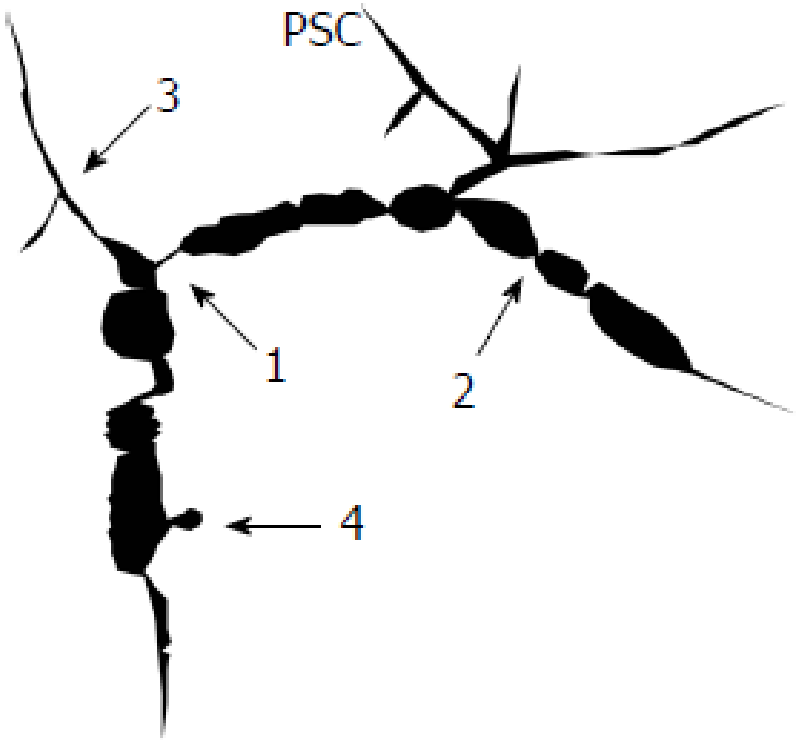

Dumonceau Ther Adv Gastro 2020
Bjornsson Am J Gastro 2004
Chapman Eur J Gastroenterol Hep 2012
Chapman Gut 2019
Kamisawa J Hepatobil Panc Sci 2019

British Society of Gastroenterology and UK-PSC guidelines for the diagnosis and management of primary sclerosing cholangitis

Michael Huw Chapman,[1,2] Douglas Thorburn,[2] Gideon M Hirschfield,[3] George G J Webster,[1] Simon M Rushbrook,[4] Graeme Alexander,[2] Jane Collier,[5] Jessica K Dyson,[6,7] David EJ Jones,[7] Imran Patanwala,[8,9] Collette Thain,[10] Martine Walmsley,[11] Stephen P Pereira[1,12]

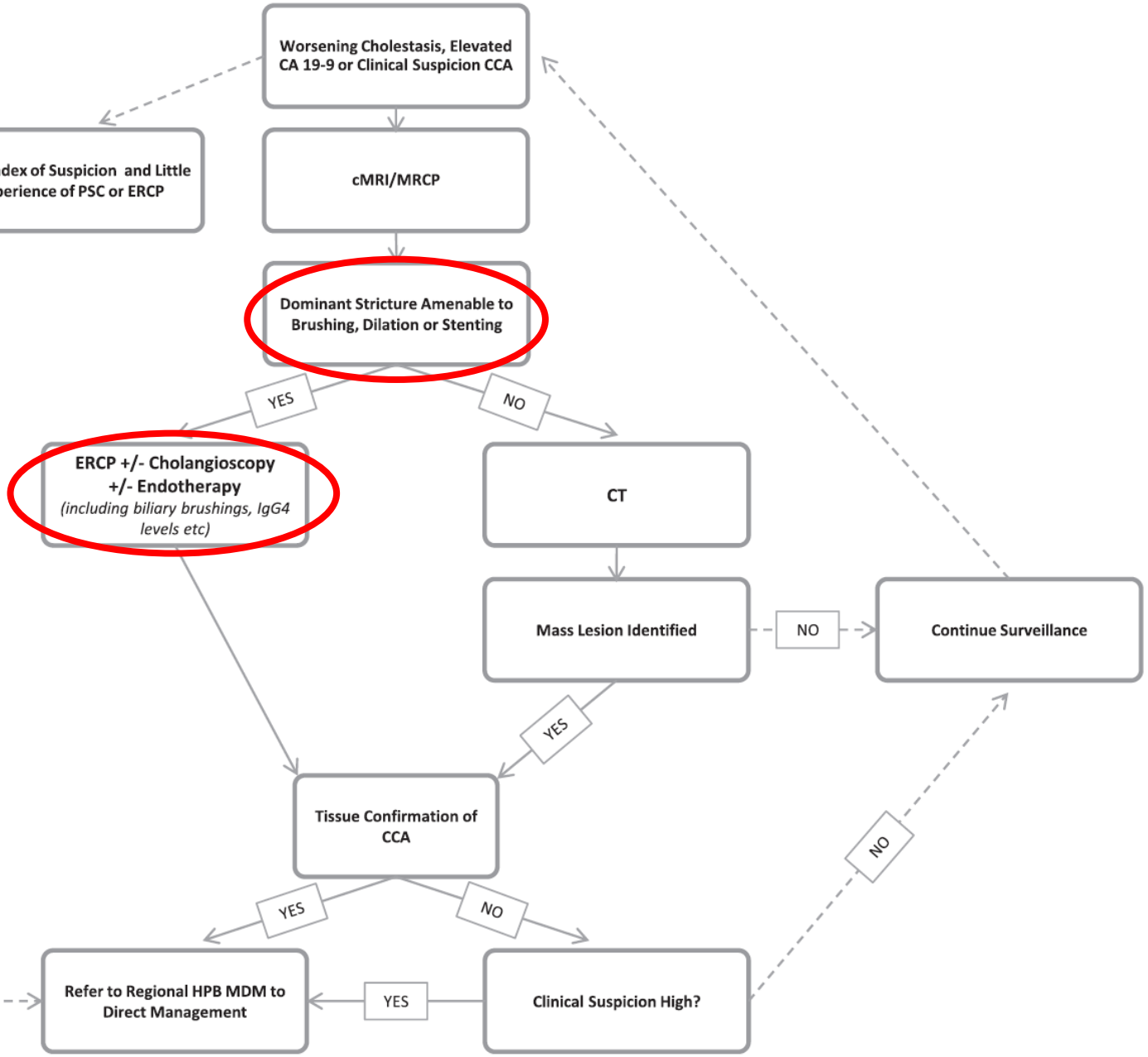

Figure 2 Algorithm for the investigation of possible cholangiocarcinoma in patients with primary sclerosing cholangitis.

Chapman Gut 2019

Distal biliary stricture

JGH Journal of Gastroenterology and Hepatology
JGHF
doi:10.1111/jgh.14955

REVIEW

International consensus statements for endoscopic management of distal biliary stricture

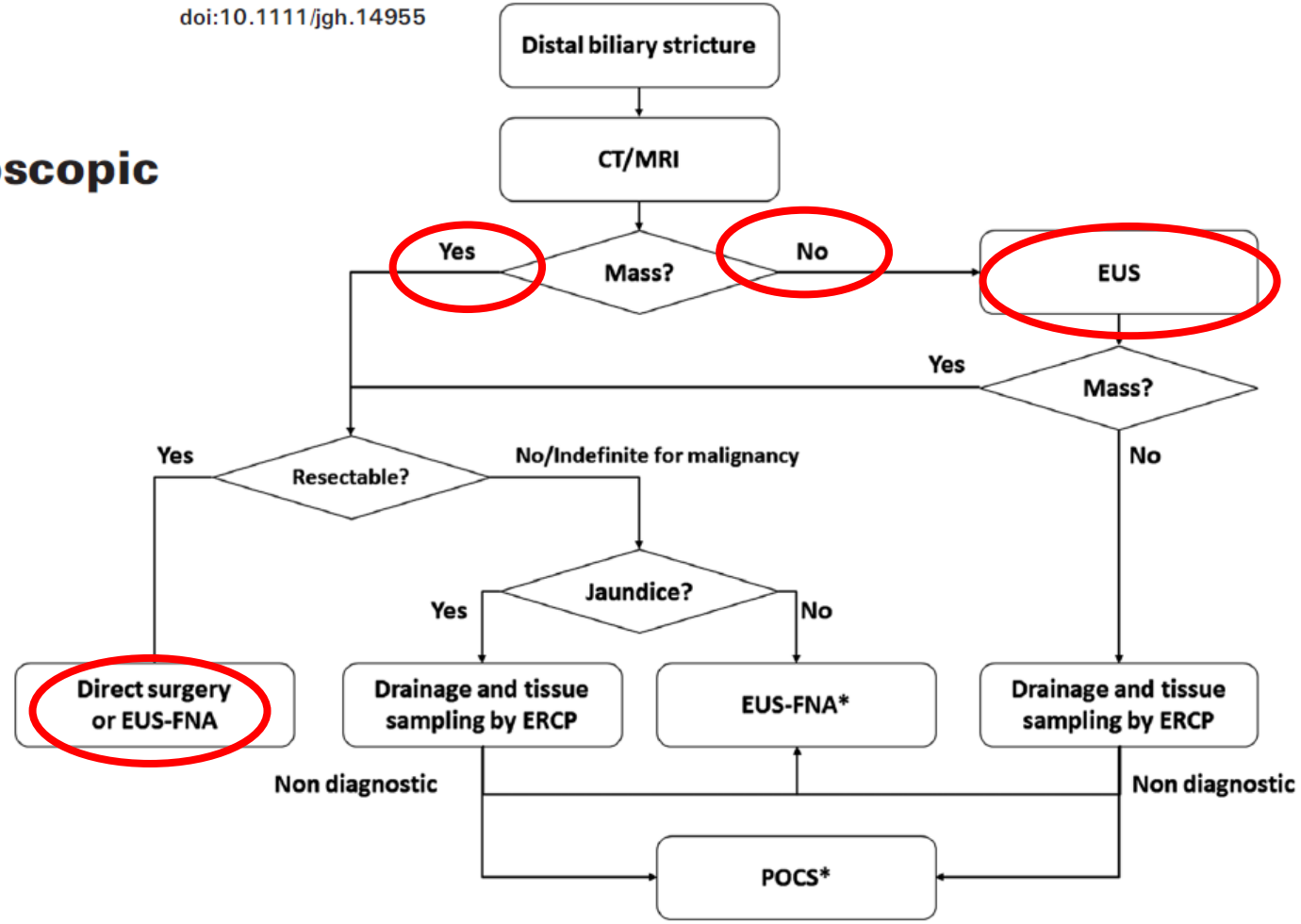

Nakai J Gastro and Hep 2020

EUS FNAB

Diagnostic yield of EUS-guided FNA for malignant biliary stricture: a systematic review and meta-analysis (CME)

Anahita Sadeghi, MD,[1,*] Mehdi Mohamadnejad, MD,[1*] Farhad Islami, MD,[2] Abbas Keshtkar, MD,[1] Mohammad Biglari, MD,[1] Reza Malekzadeh, MD,[1] Mohamad A. Eloubeidi, MD[3]

Tehran, Iran; Atlanta, Georgia; Anniston, Alabama, USA

- 20 studies, 957 patients
- Pooled **sensitivity, specificity** for diagnosis of a malignant biliary stricture was **80% and 97%** respectively
- Excluding biliary strictures in the setting of extrinsic compression from a HOP cancer, pooled sensitivity and specificity were 79% and 99%
- Distal strictures: sensitivity 83% specificity 100%
- Proximal strictures: sensitivity 76% specificity 100%
- **Adverse events**: 4/383 = **1%;** 3 self-controlled bleeding; 1 biliary peritonitis, death

Sadeghi GIE 2016

Distal biliary stricture

Endoscopic retrograde cholangiopancreatography versus endoscopic ultrasound for tissue diagnosis of malignant biliary stricture: Systematic review and meta-analysis

- 294 patients, 8 studies. Heterogeneity in terms of lesion site, techniques, design
- Sensitivities: ERCP 49%; EUS 75%; Specificities: ERCP 96.3%; EUS 100%
- PosPV: ERCP 98.3%; EUS 100%; NegPV; ERCP 34% EUS 47%
- Accuracy: ERCP 60.66%; EUS 79%

Table 4. Performance of EUS-FNA for indeterminate malignant biliary stricture

EUS-FNA	Pretest probability (%)	Sensitivity (%)	Specificity (%)	PPV (%)	NPV (%)	Accuracy (%)
Nayar 2011	54	52	100	100	54	59
Ohshima 2011	50	100	100	100	100	100
DeWitt 2005	96	77	100	100	29	83
Eloubeidi 2004	84	86	100	100	57	88
Fritscher-Ravens 2004	72	89	100	100	90	91
Weilert 2014	94	94	100	100	50	94
Novis 2010	80	68	100	100	31	73
Rosch 2004	56	46	100	100	60	70

De Moura EUS 2016

Distal biliary stricture

Endoscopic retrograde cholangiopancreatography versus endoscopic ultrasound for tissue diagnosis of malignant biliary stricture: Systematic review and meta-analysis

- 294 patients, 8 studies. Heterogeneity in terms of lesion site, techniques, design
- Sensitivities: ERCP 49%; EUS 75%; Specificities: ERCP 96.3%; EUS 100%
- PosPV: ERCP 98.3%; EUS 100%; NegPV; ERCP 34% EUS 47%
- Accuracy: ERCP 60.66%; EUS 79%

Table 3. Performance of ERCP compared to EUS-FNA for indeterminate biliary stricture

ERCP/EUS-FNA	Intervention	Pretest probability (%)	Sensitivity (%)	Especificity (%)	PPV (%)	NPV (%)	Accuracy (%)
Weilert 2014	ERCP	94	50	50	100	11	53
	EUS-FNA		94	100	100	50	94
Novis 2010	ERCP	80	49	89	95	31	59
	EUS-FNA		68	100	100	31	73
Rosch 2004	ERCP	56	46	100	100	60	70
	EUS-FNA		46	100	100	60	70

De Moura EUS 2016

EUS vs ERCP

Original article

Thieme

EUS-FNA versus ERCP for tissue diagnosis of suspect malignant biliary strictures: a prospective comparative study

OPEN ACCESS

- 50 patients underwent EUS FNA and ERCP brush cytology & forceps biopsy
- Gold standard was surgery / 6 months follow-up; proximal & distal lesions, intra- & extra-ductal lesions
- EUS FNA sensitivity, accuracy superior to ERCP (93.4%, 94% vs 60.4%, 62% - P=0.034); when **combined, no malignant lesions were missed** (97.9%, 98%)
- Similar adverse events. Greater benefit for EUS in extraductal lesions, lesions > 1.5cm

▶ **Table 2** Anatomical location and final anatomopathological results.

	Proximal X Distal		Intra X Extra-ductal		ERCP Tissue Sampling				EUS-FNA				ERCP + EUS Tissue Sampling		
	Proximal	Distal	Intra ductal	Extra ductal	Malignant	Susp.	Benign	Fail	Malignant	Inc.	Benign	Fail	Malignant	Susp.	Benign
n	15	35	19	31	29	4	11	6	45	2	2	1	47	1	2
%	30%	70%	38%	62%	58%	8%	22%	12%	90%	4%	4%	2%	94%	2%	4%

De Moura Endo Int Op 2018

Incremental benefit

—Review Article—

The incremental benefit of EUS for the identification of malignancy in indeterminate extrahepatic biliary strictures: A systematic review and meta-analysis

Albert Chiang, Martin Theriault[1], Misbah Salim[2], Paul Damien James[2]

- EUS increases the identification of malignancy for indeterminate biliary strictures following a nondiagnostic ERCP

- **Incremental benefit** is **greater** for **distal biliary strictures** or when there is compression by an **extrinsic mass**.

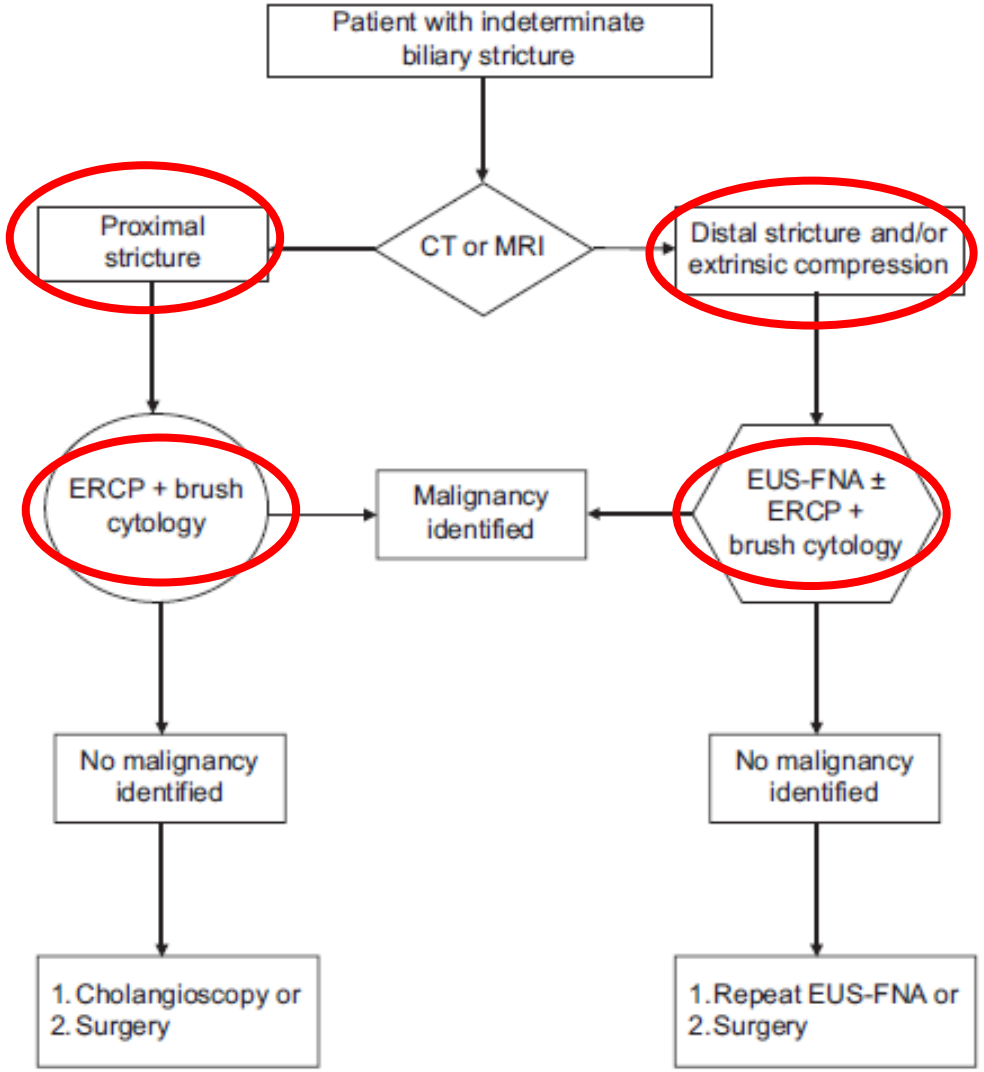

Chiang EUS 2019

Combined ERCP, EUS

JGH Journal of Gastroenterology and Hepatology
JGHF
doi:10.1111/jgh.14528

BILIARY AND PANCREATIC

Same-session endoscopic ultrasound-guided fine needle aspiration and endoscopic retrograde cholangiopancreatography-based tissue sampling in suspected malignant biliary obstruction: A multicenter experience

- 263 patients with suspected malignant biliary obstruction who underwent same session EUS & ERCP
- EUS FNA sensitivity, accuracy: 73.6%, 76.1%
- ERCP sensitivity, accuracy: 56.5%, 60.5%
- **EUS/ERCP combination sensitivity, accuracy: 85.8%, 87.1%**
- Overall performance: EUS/ERCP > EUS FNA alone > ERCP ($P < 0.001$) but **benefit of EUS alone was for pancreatic masses**
- **Combined EUS/ERCP was superior to EUS or ERCP for biliary lesions**

Jo J Gastro Hepatol 2019

23 yr old man, known with UC

ALP: 149 -> 236 -> 228

GGT: 299 -> 514 ->529

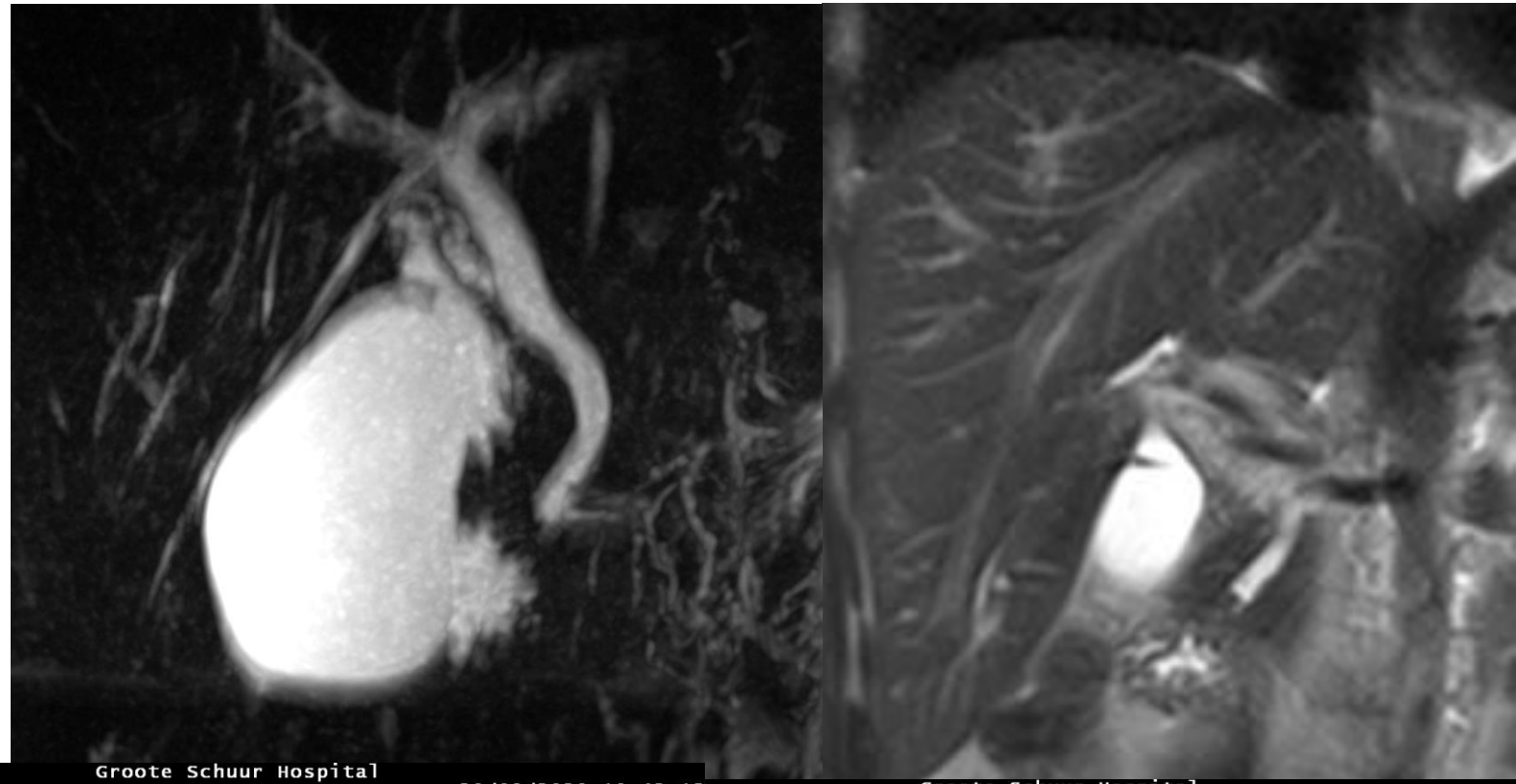

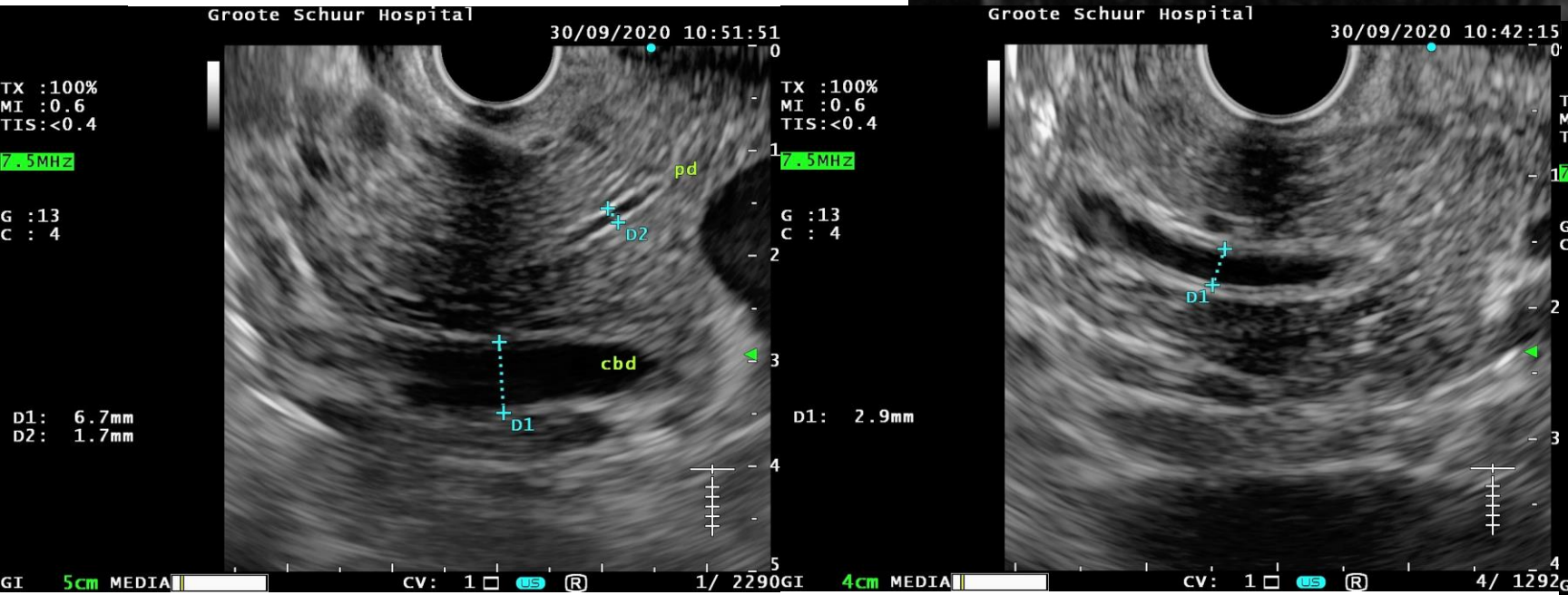

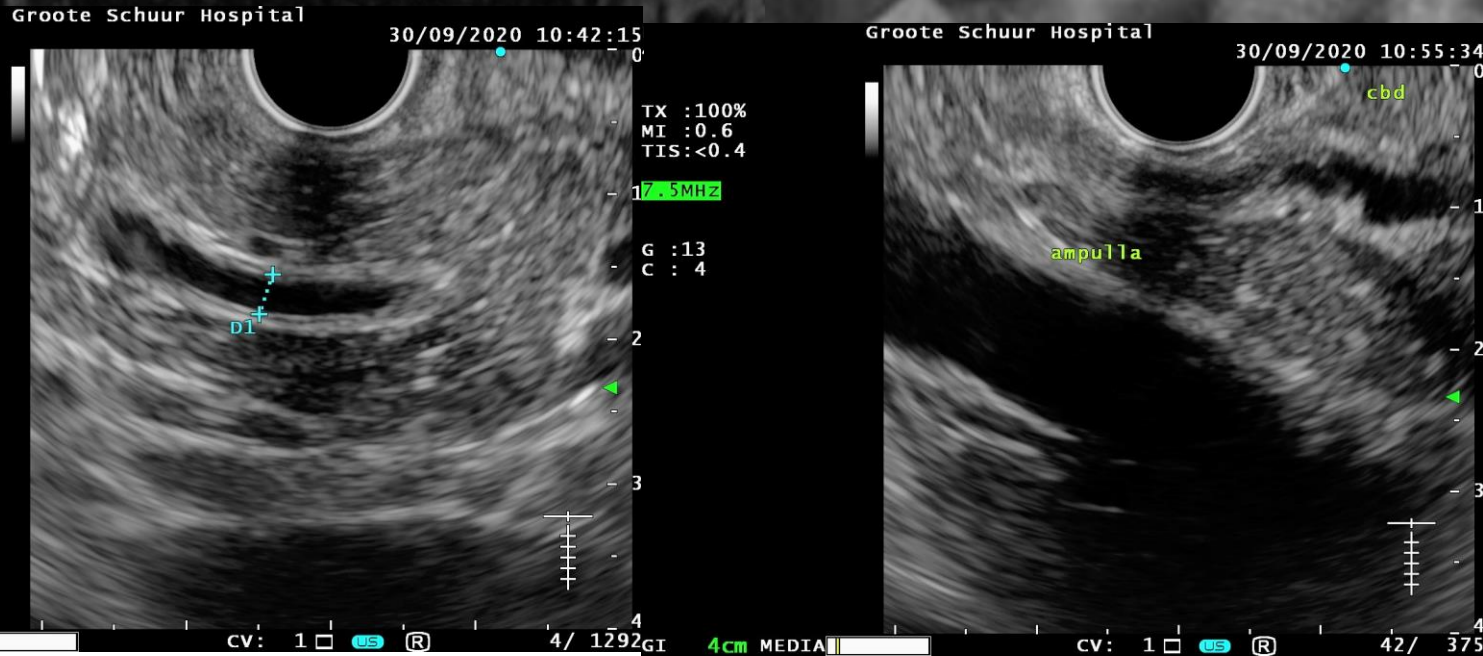

60 yr old man
Significant etoh history
Fluctuating bilirubin level

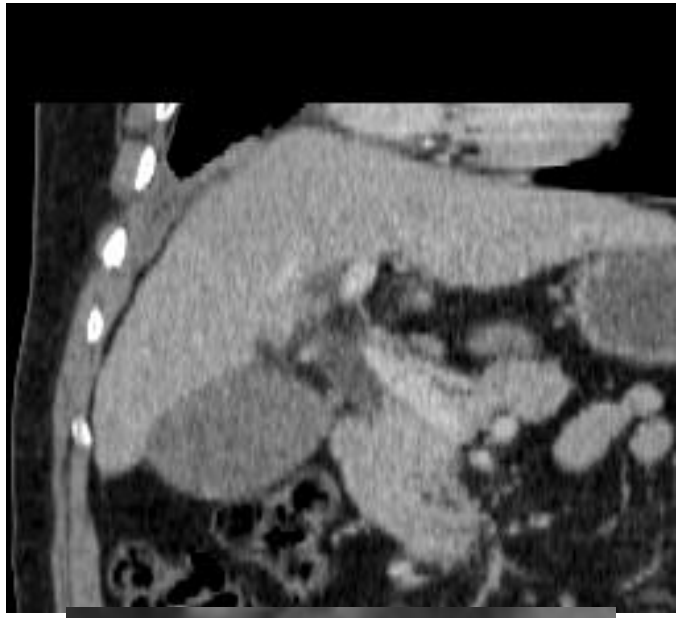

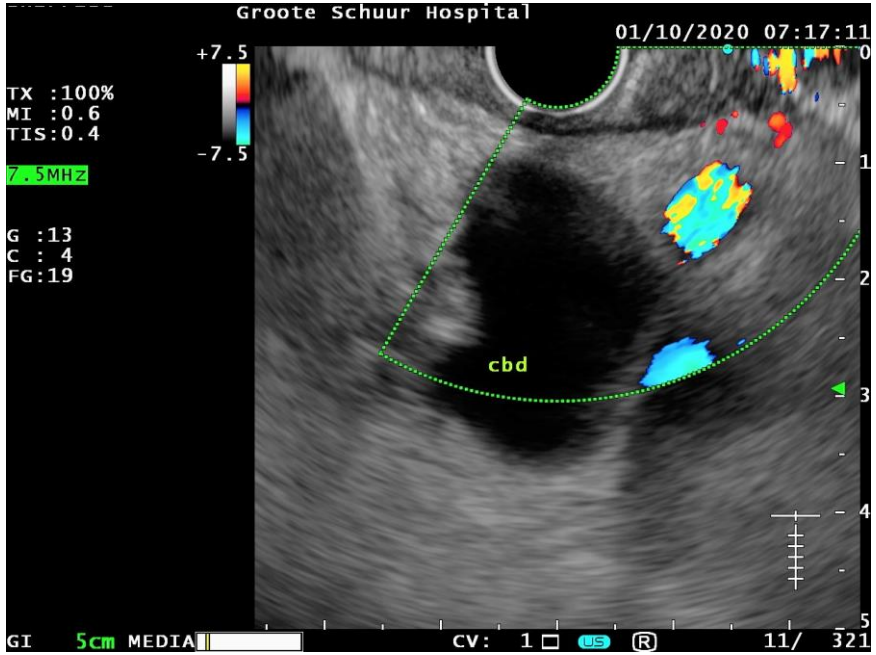

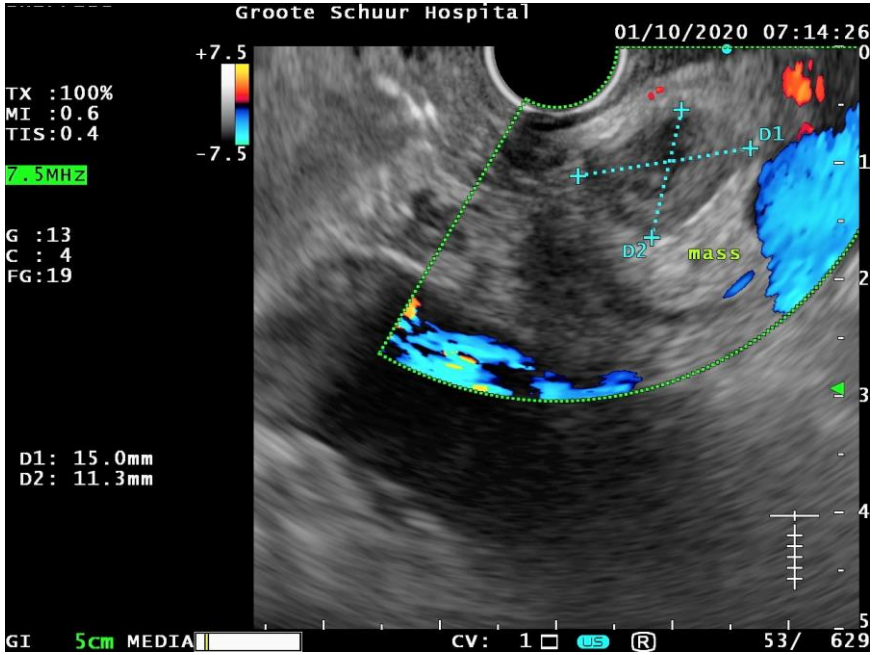

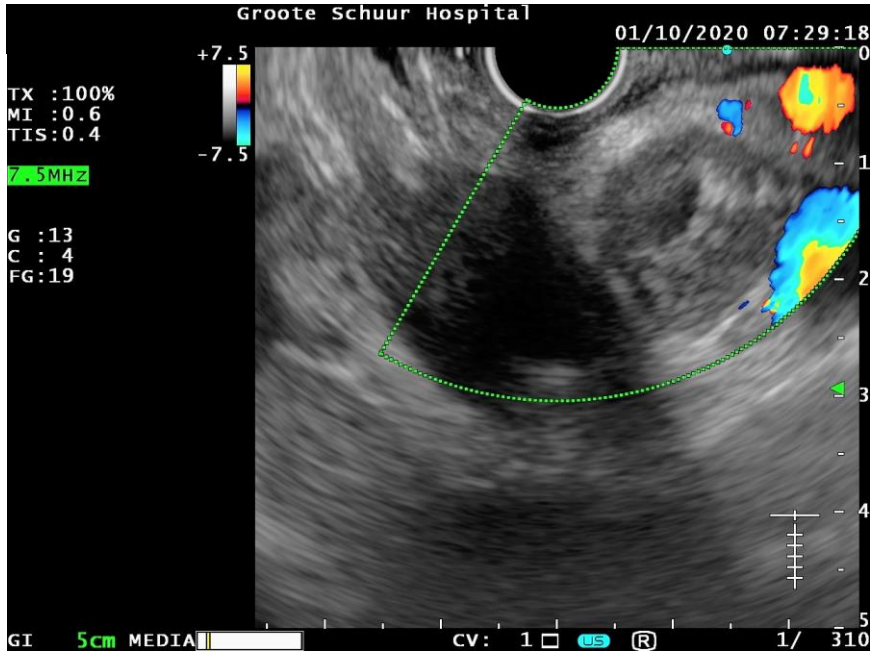

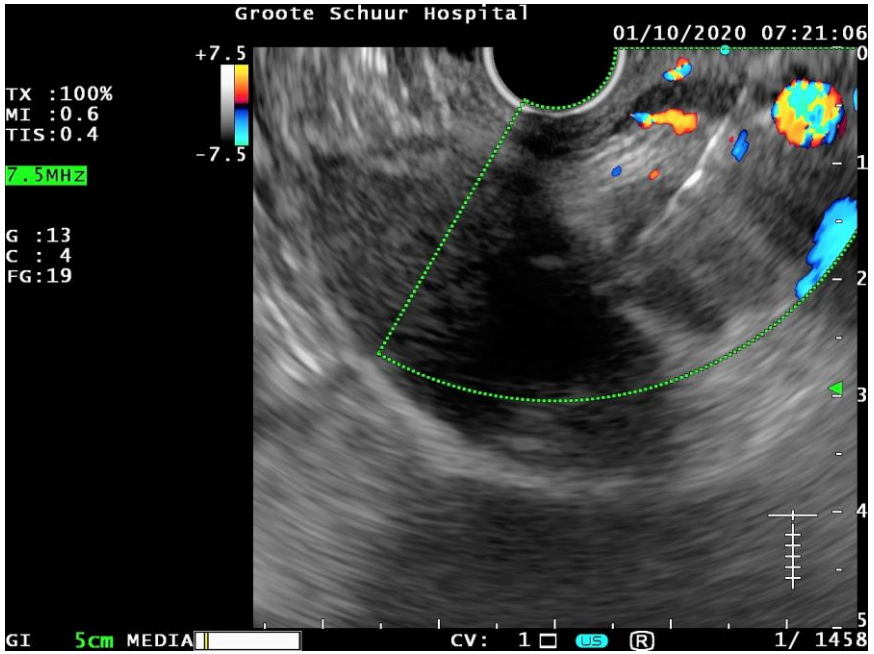

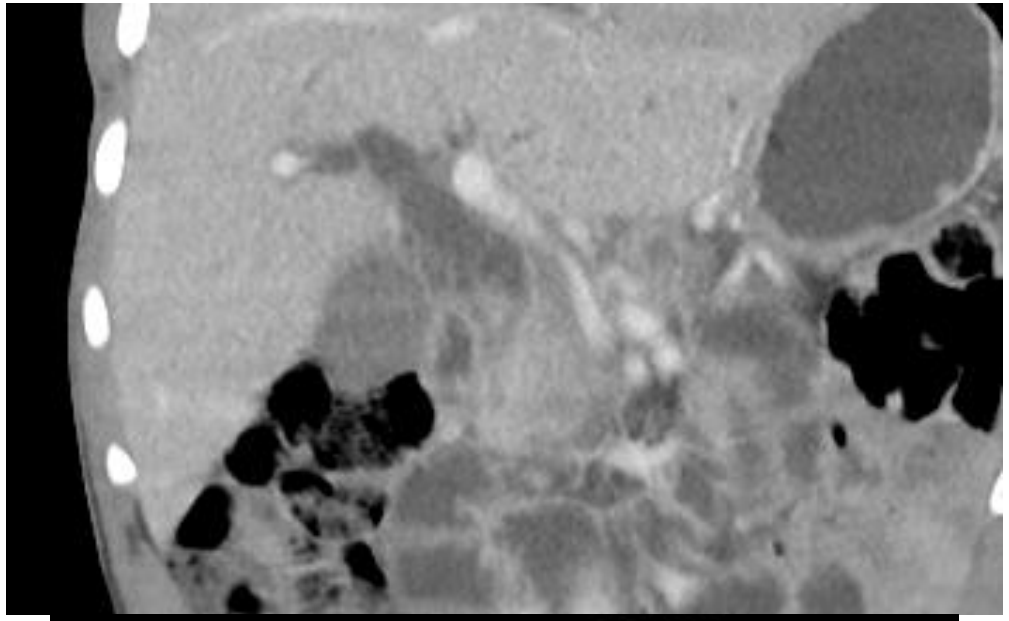

48 yr old man presented with painless, obstructive jaundice, total bilirubin of 220

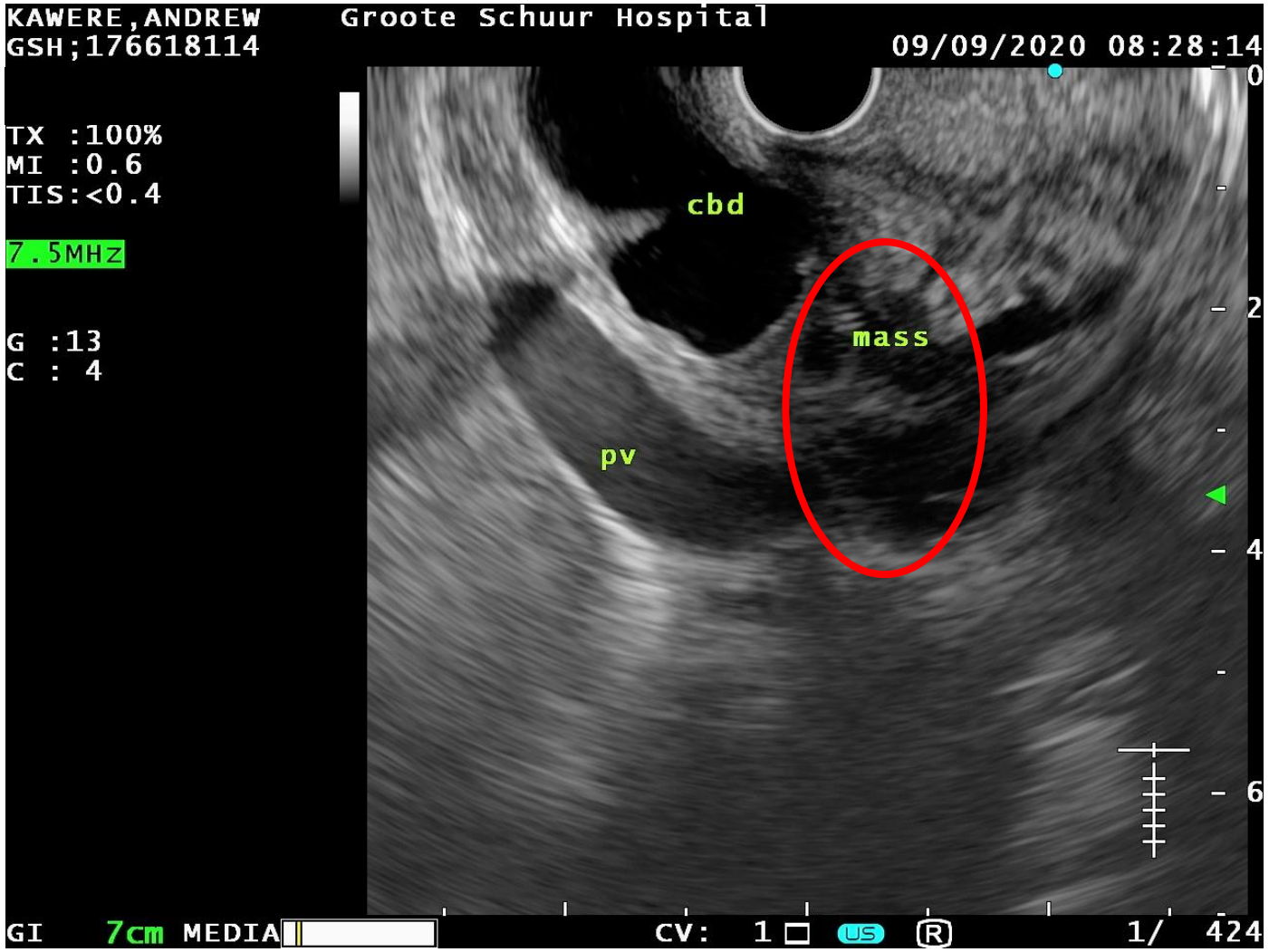

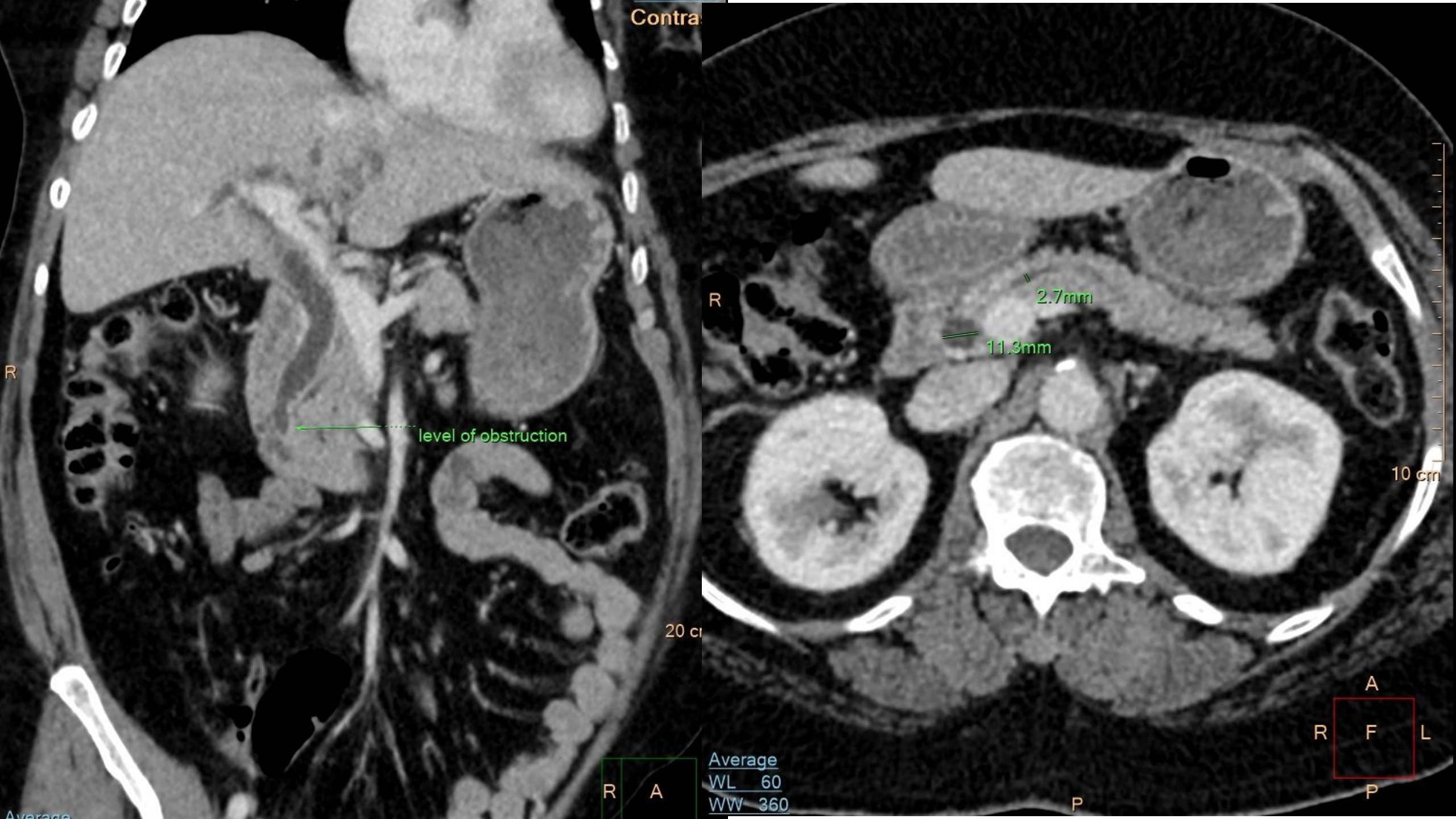
Contra
R
level of obstruction
20 cm
R
A
Average
WL 60
WW 360
R
2.7mm
11.3mm
10 cm
A
R
F
L
P
P

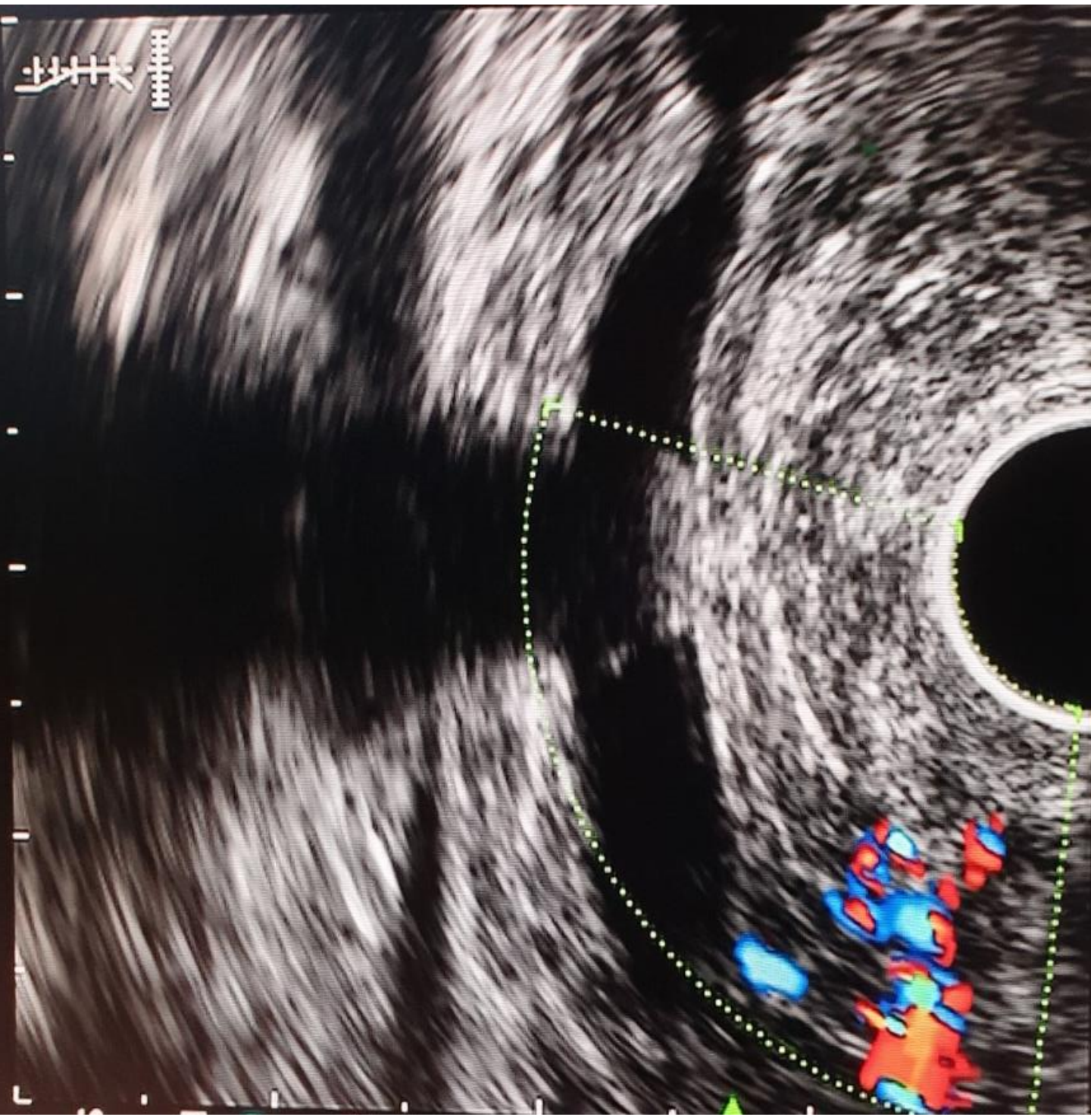

Adjunctive techniques – pathological assessment

- **Standardised descriptions** should be used.
  - nondiagnostic, negative, atypical, neoplastic (benign or other), suspicious and positive
  - Caution in interpreting **"atypia"** in the setting of PSC or prior stent placement
  - Dedicated cytopathologists increases sensitivity maintaining sensitivity
- Rapid on-site evaluation (**ROSE**)
  - Can increase sensitivity of ERCP brushings / biopsy and reduce sampling in EUS FNAB
- Fluorescent in situ hybridisation (**FISH**) cytological examination
  - uses fuorescence-labeled probes to detect chromosomal abnormalities in cells obtained via routine biliary brushings
- Next-generation sequencing, microRNA analysis are additional ancillary techniques but are not widely available

Wight Cytopathology 2004
Brooks Dig Dis Sci 2018

FISH
EUS
Cholangioscopy

Digestive Diseases and Sciences (2018) 63:636–644
https://doi.org/10.1007/s10620-018-4906-x

ORIGINAL ARTICLE

CrossMark

Role of Fluorescent In Situ Hybridization, Cholangioscopic Biopsies, and EUS-FNA in the Evaluation of Biliary Strictures

- FISH has been reported to **increase the sensitivity of brushings** in comparison to cytology alone
- Sensitivity of **FISH** polysomy/9p21-deletion **with cytology** compared to cytology alone was 63% vs 35% ($p < 0.05$).
- **EUS FNAB for distal strictures** cytology negative increased sensitivity from 33% to 93% over cytology alone ($p<0.001$)
- **Cholangioscopic biopsy for proximal strictures** cytology negative increased sensitivity from 48 to 76% ($p=0.05$)
- Suggested
  - **Distal strictures: cytology, EUS FNA – FISH if negative**
  - **Proximal strictures: cytology, FISH – Cholangioscopic biopsy if negative**

Brooks Dig Dis Sci 2018

Hilar strictures

- EUS FNA is less suitable for hilar / intrahepatic strictures
  - Visualisation is more difficult
  - EUS FNA of hilar lesions is discouraged due to concerns over seeding



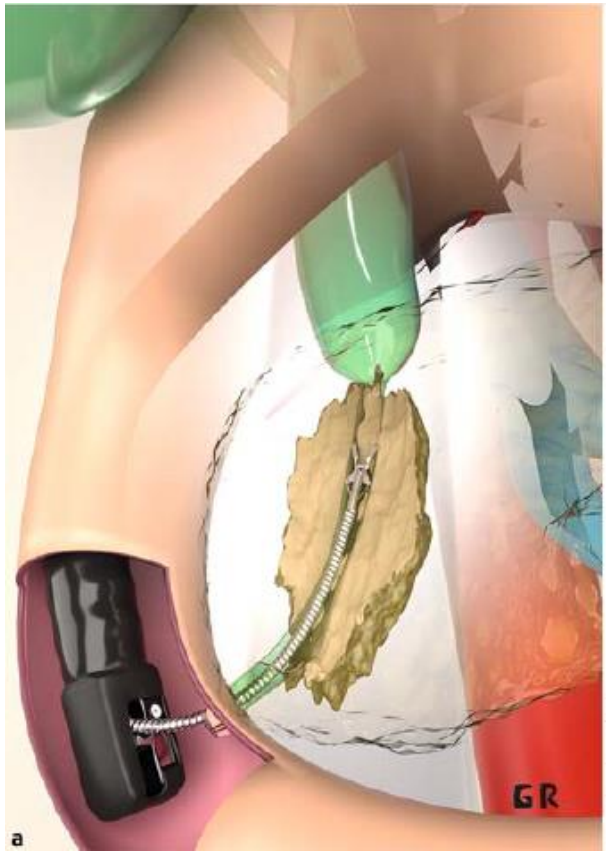

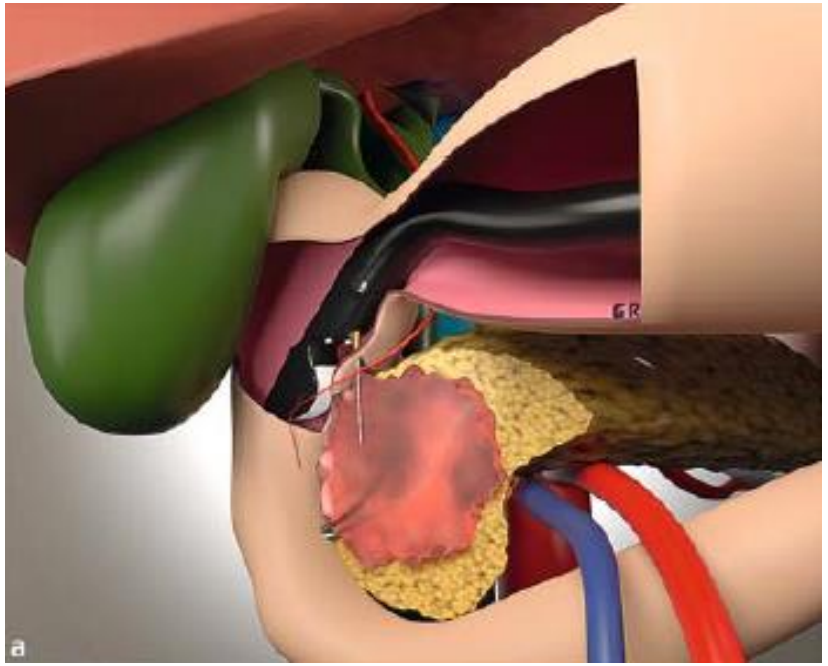

De Moura Endo Int Op 2018

Cholangioscopy

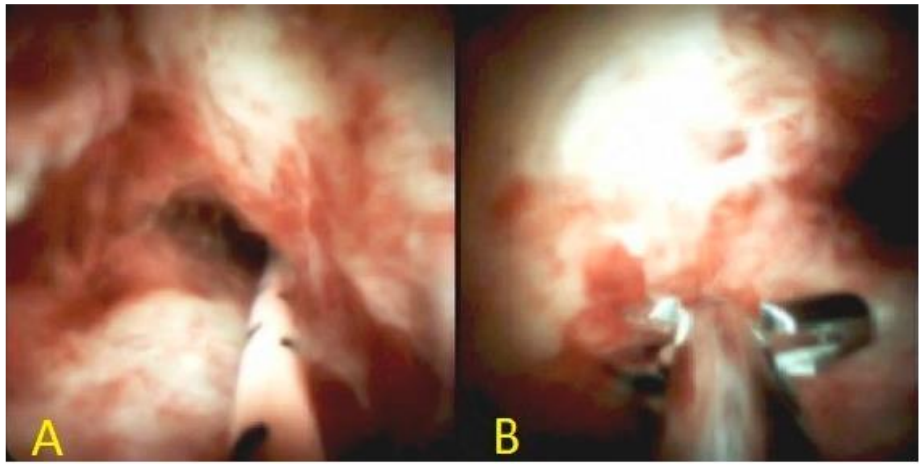

- **Sensitivity / specificity** of cholangioscopy **images 85%/83%** for diagnosis of malignant strictures; dilated / tortous vessels are strongest indicator of malignancy
- Cholangioscopy guided **biopsy sensitivity / specificity of 60%/98%**
- Often performed after failed ERCP diagnosis due to it's own limitations in sensitivity, cost and potential for complications

Dumonceau Ther Adv Gastro 2020
Navaneethan GIE 2015
Dorrell Diagnostics 2020

Intraductal ultrasound

- Ideally performed before stent placement
- Limited comparative data but some evidence it may distinguish benign from malignant lesions better than EUS, particularly in more **proximal lesions**
- **Accuracy >80% following negative ERCP cytology / histology**; can also **aid directed biopsy** improving the accuracy of this modality
- Limited by cost, need for expertise, availability, fragility of probes

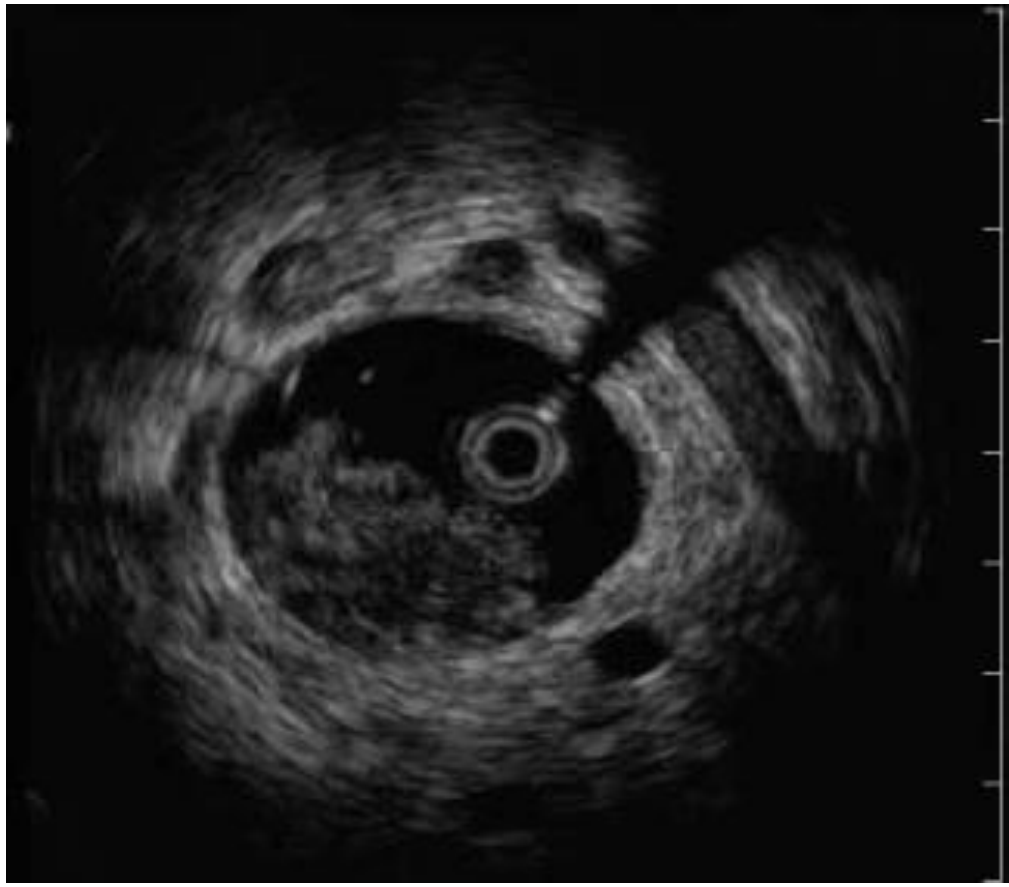

Dumonceau Ther Adv Gastro 2020
Victor W J Gastro 2012

Confocal laser endomicroscopy

- Limited by high cost, specialist expertise, low specificity
- Sensitivity / specificity 87%, 76% for discriminating benign and malignant pancreaticobiliary strictures

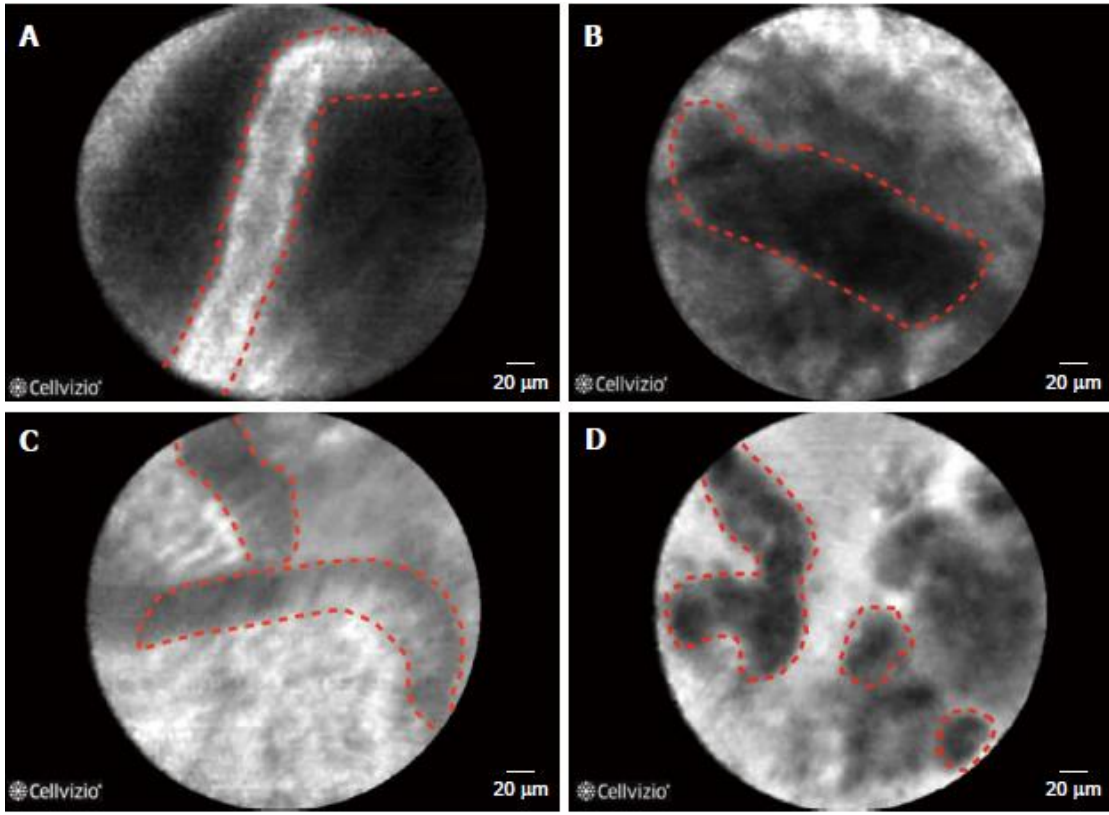

Xu GI Endo Clin N am 2015
Gao Scand J Gastroenterol 2018
Almadi W J Gastro 2015

Conclusion

- Assessment of biliary strictures can be complex, utilising **multiple modalities** in a **multi-disciplinary** approach
- Adequate **clinical assessment, biochemistry / biomarkers** and optimal **non-invasive cholangiography** are essential components of initial evaluation
- The presence of a **mass lesion** in association with a stricture is highly suspicious for a malignancy
- Where differentiation between benign and malignant disease requires **tissue acquisition**, the approach should differentiate between extra-hepatic and hilar / intra-hepatic strictures
  - **Extra-hepatic strictures** are best evaluated with a **combined ERCP / EUS** approach
  - **Hilar / intra-hepatic** evaluation requires advanced intra-luminal techniques utilising **ERCP together with cholangioscopy, IDUS or confocal laser microscopy** depending on local practice